

Managing Complex Traumatic Wounds

Military Working Dogs



Shane J. Andrews DVM, DACVS-SA
Solace Veterinary Specialty Center
Lieutenant Colonel, United States Army Reserve






1

Disclaimer

The views expressed in this presentation are those of the authors and do not reflect the official policy or position of the Department of the Army, Department of Defense, or the United States Government.


No conflicts of interest.



2

Agenda

- Background
- Importance of MWDs
- Roles of care
- Case studies
- Conclusion




3

3



4



5



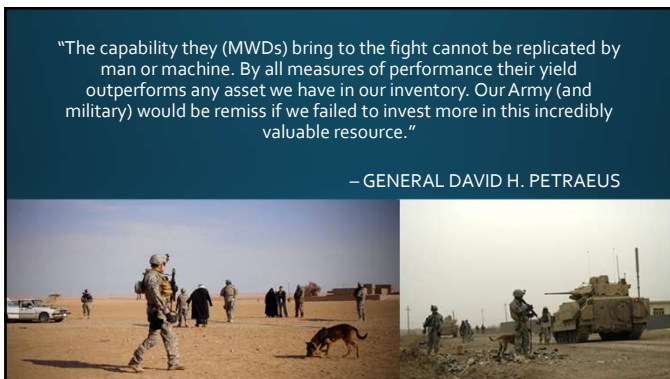
6



7



8



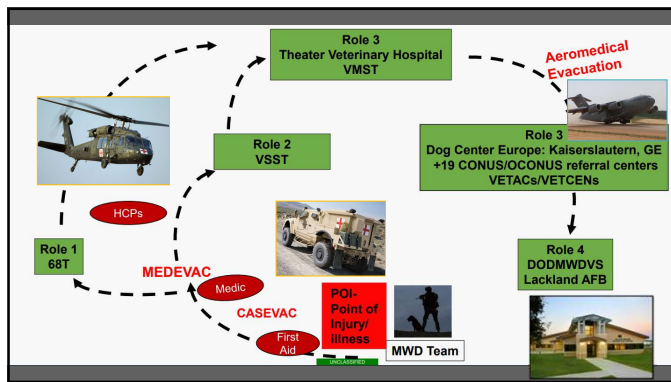
9

MEDEVAC Platforms


- First responders/handlers provide initial treatment and triage the patient
- MWDs MEDEVAC to the first level of veterinary care in theater
- If patient treatment requirements exceed the in theater capabilities, MWDs are flown to higher echelon of care



10



11



12



13

14


Junctional Hemorrhage

- Wounds in the:
 - Groin
 - Caudal thigh and perineal region
 - Axilla (Armpits) and shoulders
 - Base of the neck

15

Junctional Hemorrhage


Wounds that may result in junctional hemorrhage in **K9s** are typically caused by dismounted **IED (Improvised Explosive Device)** attacks and **GSW (Gun Shot Wounds)**.




Courtesy of Dr. Kevin Winkler

16

Extremity Wounds



Windlass Tourniquets: Not Effective




17

Tourniquets

- The only "tourniquet" that should be considered for massive extremity hemorrhage in a K9 casualty is a stretchable and elastic tourniquet such as the **SWAT-T**.
 - (H&H Med Corp; <https://www.swat-t.com/>).
- Serves as an effective pressure bandage




18

Loaded Weapon




The collage consists of four images: 1) A dog barking with its mouth open. 2) A dog wearing a black muzzle. 3) A close-up of a dog's leg with a severe, bloody wound. 4) A close-up of a human hand with a bloody wound on the palm.

19

Successful Wound Healing

- Consider all factors involved:
 - Management
 - Patient
 - Wound
- 4 Tenets of Wound Healing
 - Cleanse
 - Debride
 - Lavage
 - Dress
 - Repeat



The image shows a dog's head with a severe, bloody wound on its neck. A surgical instrument is being used to treat the wound.

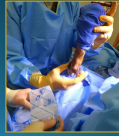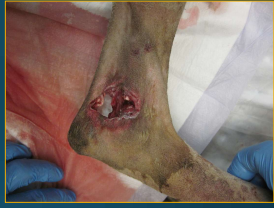20



21

Case #1

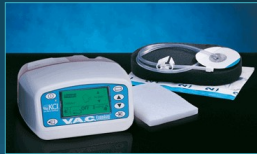- 2 yr male GSD
- Shrapnel wound to right hind
- Stabilized at a FOB (forward operating base)
- MEDEVAC to Bagram Airfield, Afghanistan
- AEROVAC to Role 3 in Germany 8 days post-injury



22

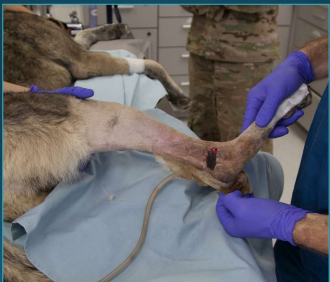Negative Pressure Wound Therapy

- Continuous or intermittent negative pressure
- -125 mmHg
- Decreases interstitial edema
- Increases hydrostatic pressure in capillaries
- Drainage of wound – maintains environment
- Increases bacterial clearance
- Gauze or foam-based
- Enhances early clinical wound healing
- Promotes granulation tissue

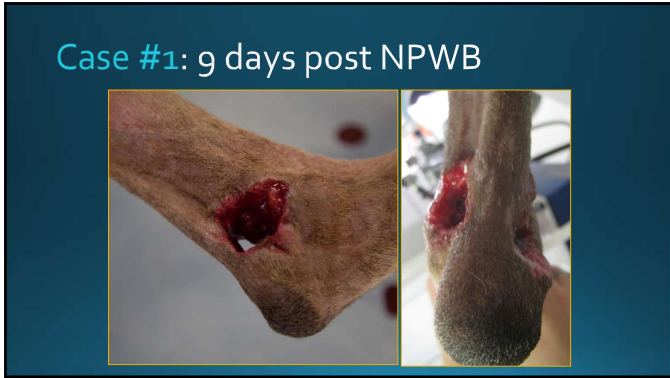

23

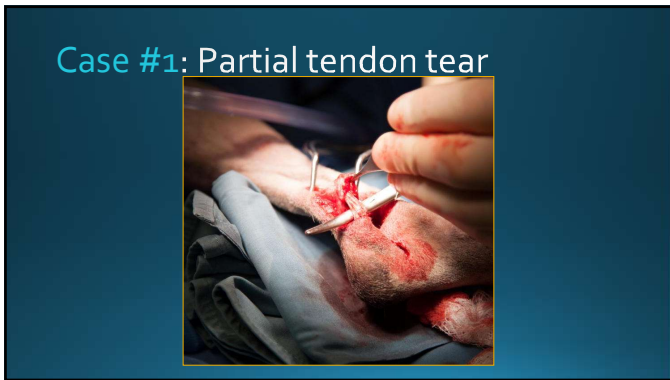Case #1



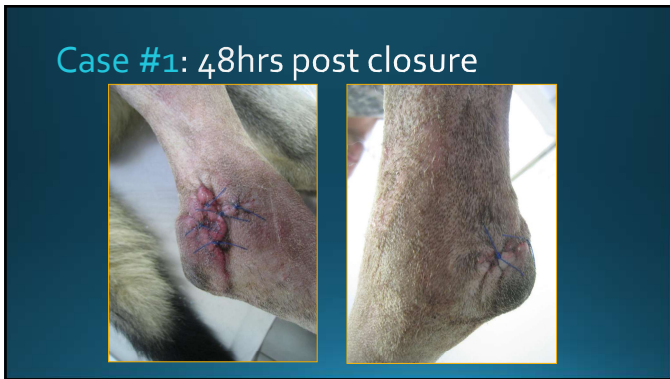24



25



26



27

Case #1



28



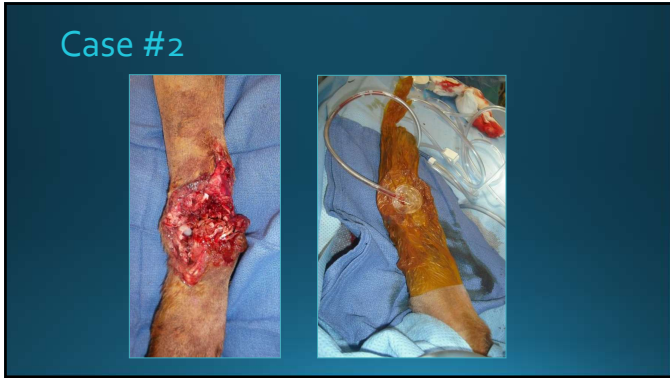29

Case #2

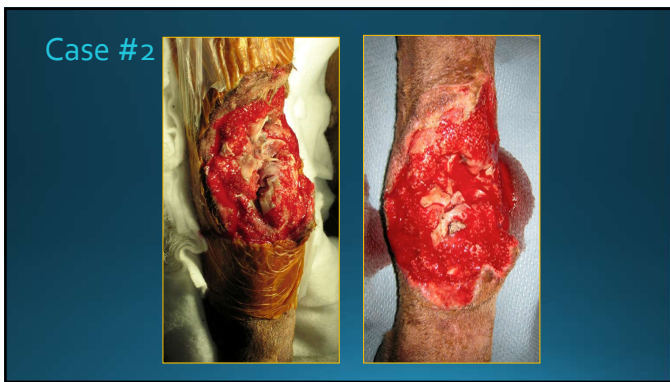- 6 yr male Belgian Malinois, Allied Force
- Gun shot wound to the right distal antebrachium
- Stabilized at Kandahar AB
 - NPWT placed on the limb and leg splinted
- Arrived at Bagram Airfield three days after initial injury
- AEROVAC to Germany



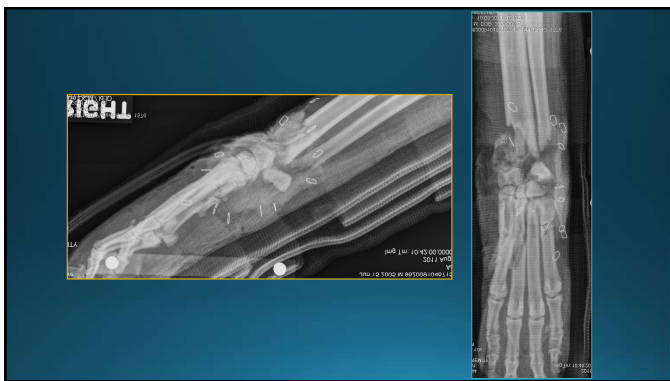30



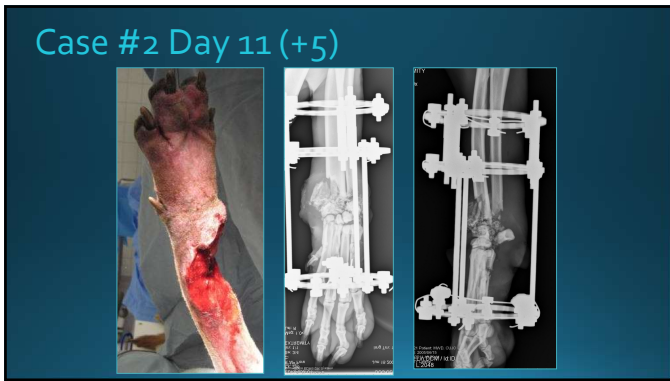
31



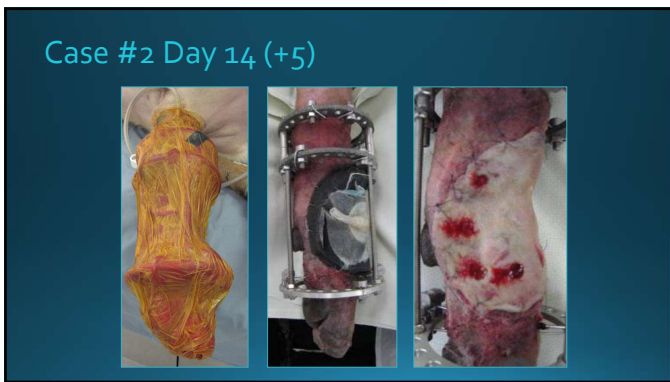
32



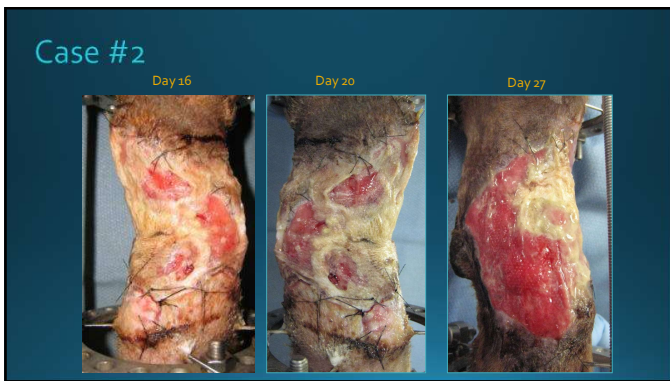33



34

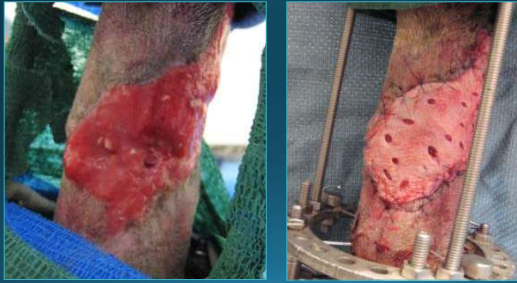

35



36

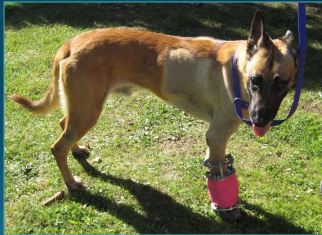Case #2 Day42 (+5)



37

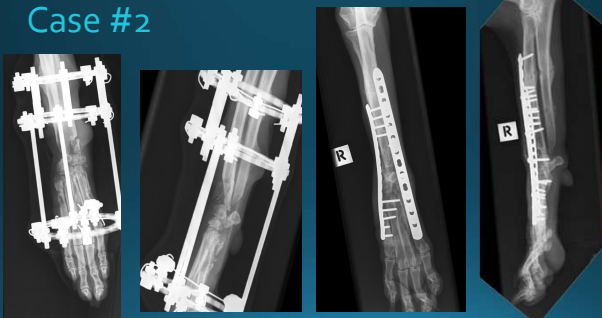
Case #2

- 49 days in Germany
- Multiple bandage changes
- One external fixator placement
- Two free skin graft procedures

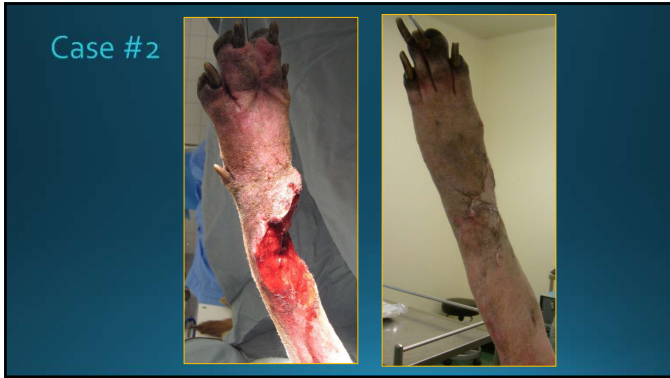

38


Case #2



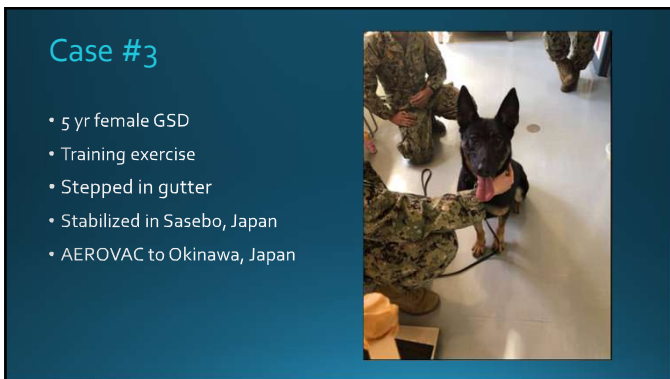
39



40



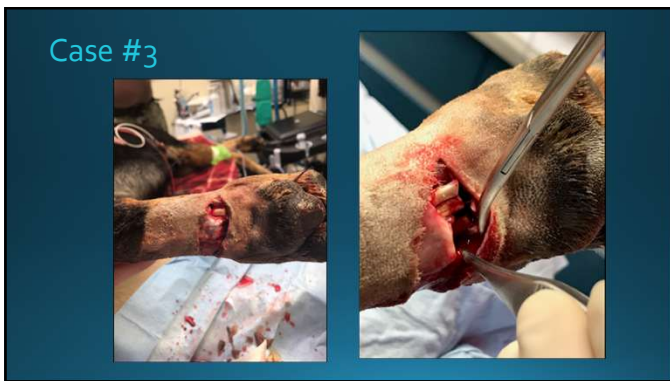
41

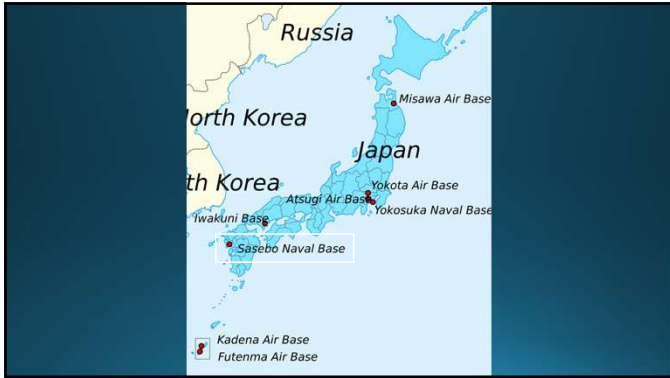

42





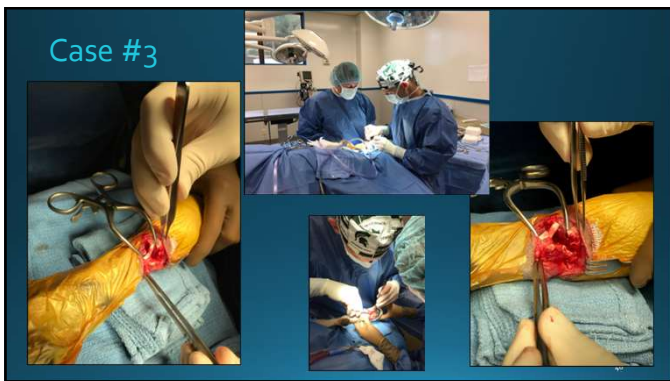




46



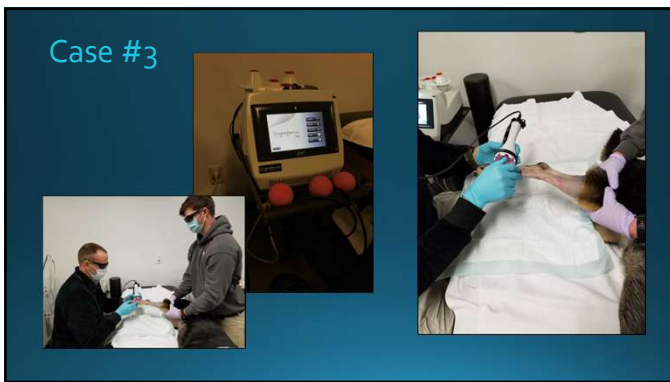
47




48



49



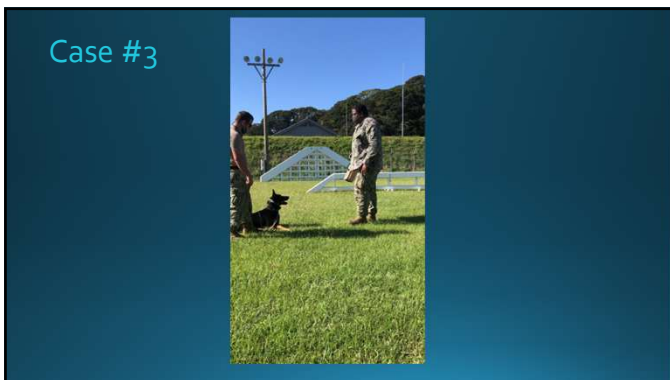
50




51




52




53



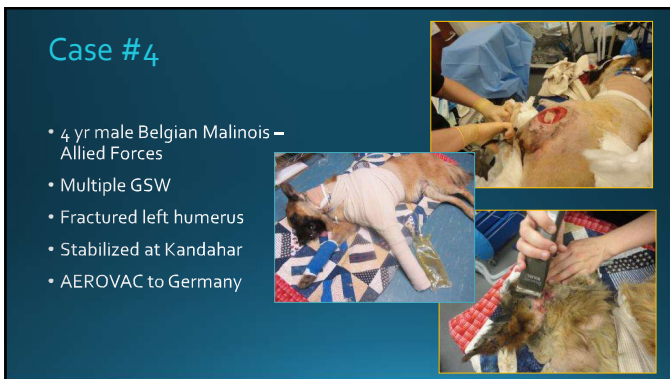54



55



56



57

Case #4



The first photograph shows a dog inside a metal transport cage with a bright green light bar. The second photograph shows the same dog sitting on a tiled floor, wearing a clear plastic cone collar (E-collar).

61



62

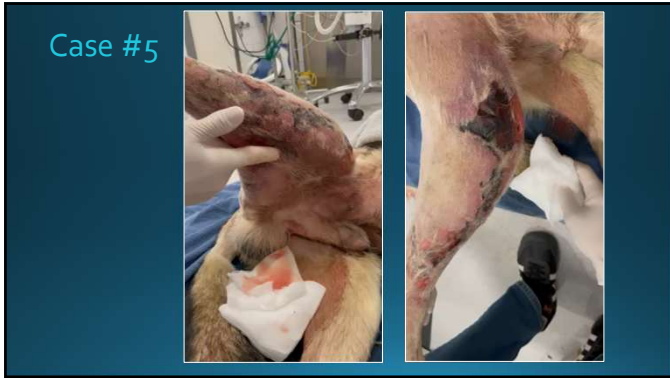Case #5

- 4 yr female GSD
- Unknown trauma to perianal area
- Stabilized in Naples, Italy
- Developed sepsis
- AEROVAC to Germany

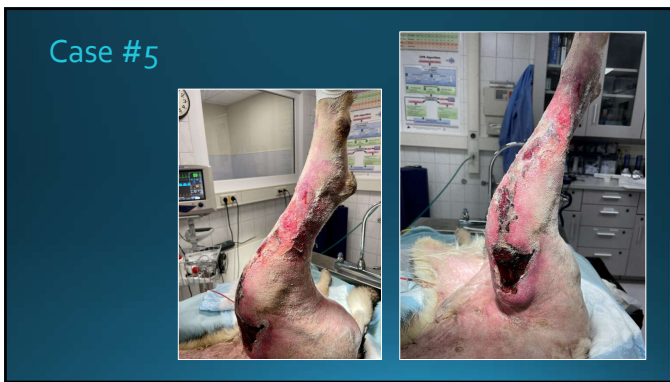

The photograph shows a German Shepherd dog sitting on a light-colored surface, looking towards the camera with its mouth open.

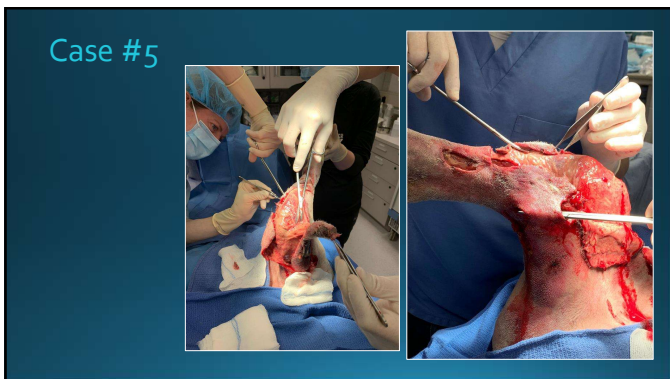
63



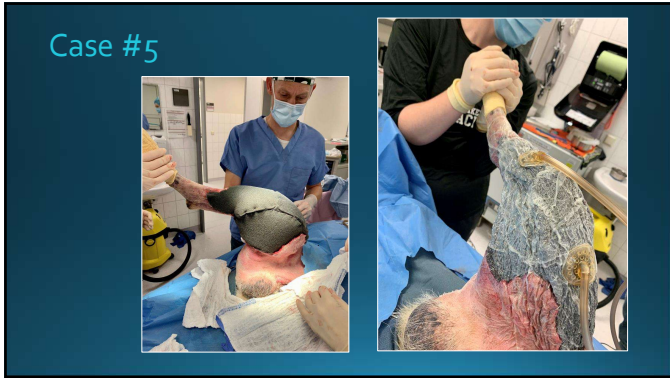
64




65



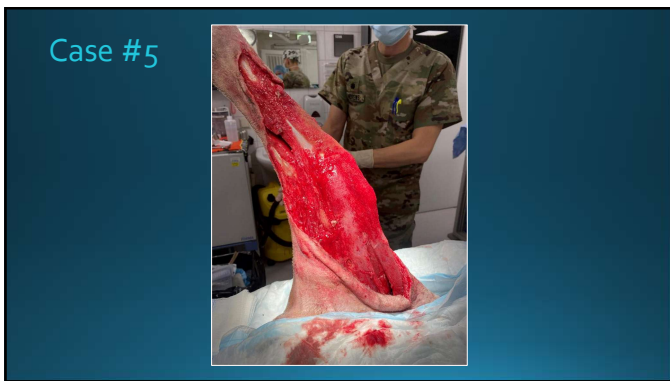66



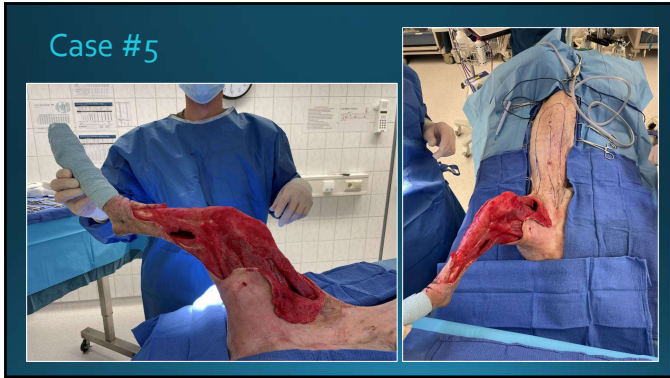
67



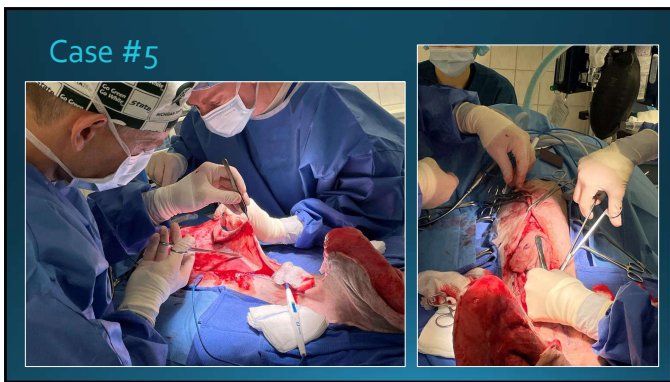
68



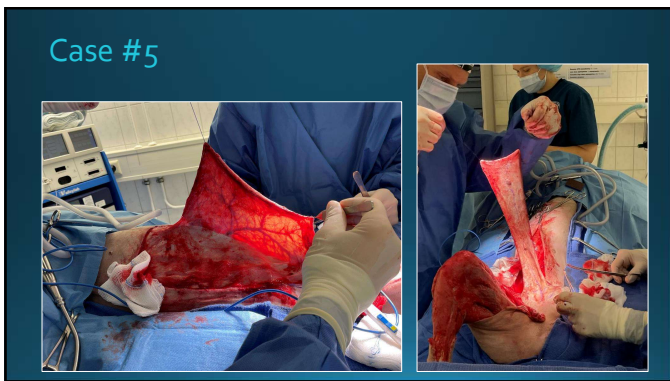
69



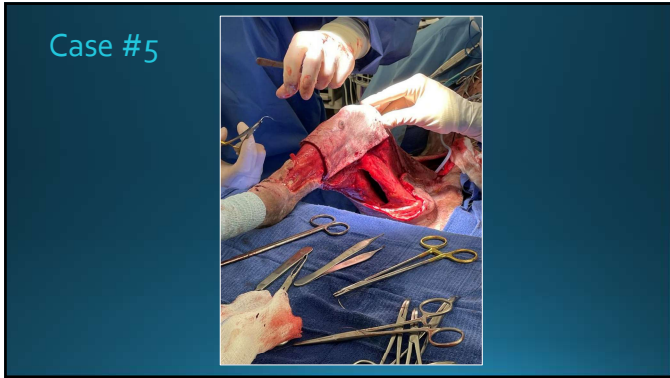
70



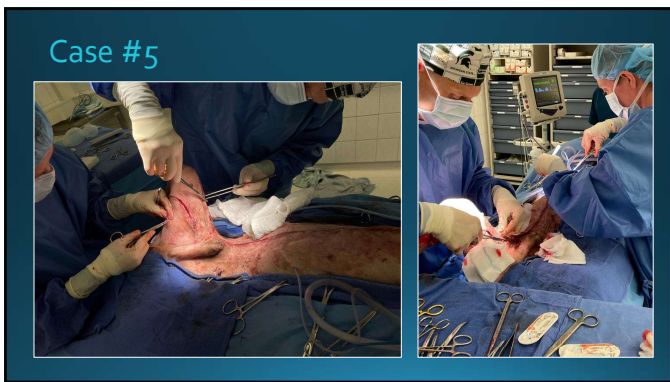
71



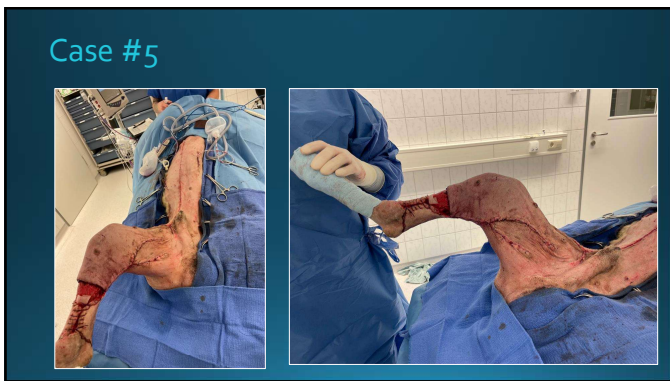
72



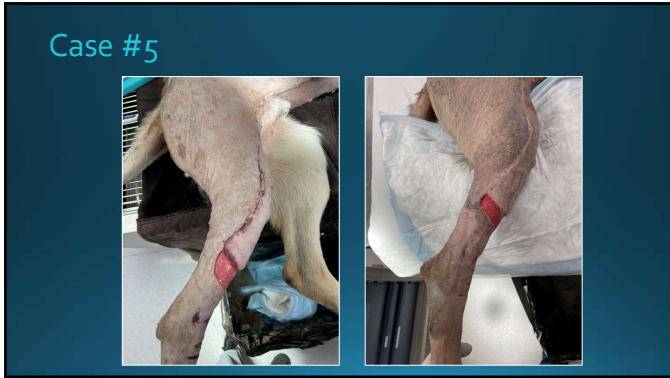73



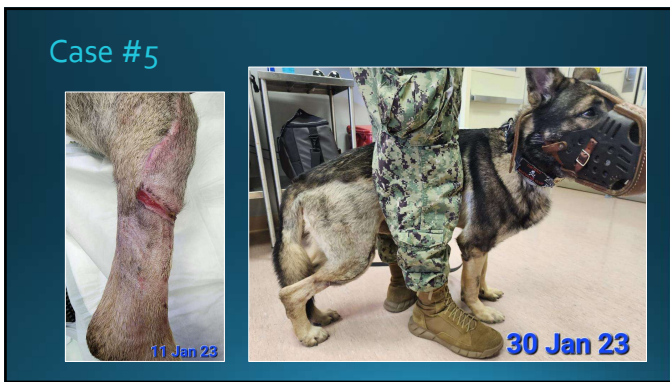74



75



76



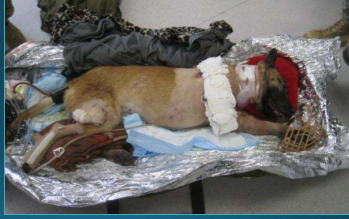77



78

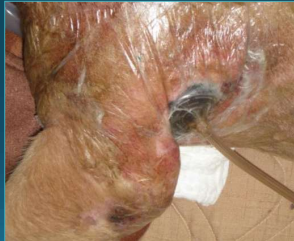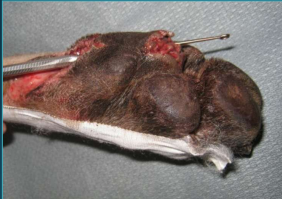Case #6

- 4 yr female Belgian Malinois
- Ambushed and sustained GSW to all four limbs
- Severed radial artery = right forelimb amputation
- Placement of NPWT
- AEROVAC to Germany



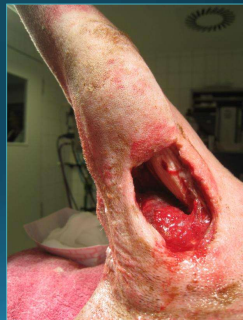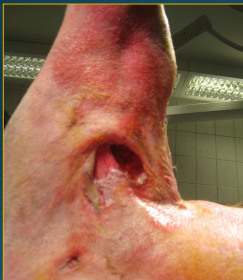79

Case #6



80

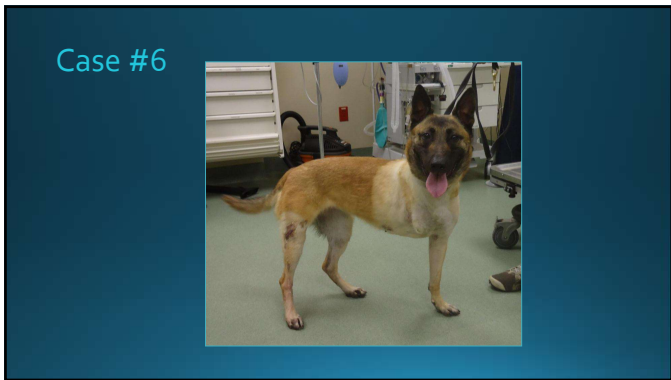Case #6




81



82



83



84

Conclusion

- Military Working Dogs sustain severe injuries requiring complex treatment.
- The use of NPWT has been instrumental to the recovery of many battle injured MWDs.
- Teamwork approach
- Consider all factors involved
- 4 tenets of wound care

85

Acknowledgments

- COL Kent Vince
- LTC Jacque Parker
- CPT Anna Mullins
- CPT Catie Cook
- CPT Alyssa Balzar
- LTC Dianne Callette
- 68Ts (vet techs) of DCE
- LTC Jim Giles
- LTC Jennifer Beck
- MAJ Todd Thomas
- MAJ Katie Barry
- MAJ Jamie Brown
- 64th 72nd & 463rd Medical Detachment (VS)
- Dr. Mark Glyde



86



87
